

Original Article

Increased expression of iASPP correlates with poor prognosis in FIGO IA2–IIA cervical adenocarcinoma following a curative resection

Fanming Kong^{1*}, Xiaofeng Shi^{2*}, Huzi Li¹, Pu Li³, Jianchun Yu¹, XiaoJiang Li¹, Jun Chen¹, Yiyu Sun¹, Yingjie Jia¹

¹Department of Oncology, First Teaching Hospital of Tianjin University of TCM, Anshanxi Road, Nankai District, Tianjin 300193, China; ²Department of ICU, Tianjin First Center Hospital, Fukang Road, Tianjin 300192, China; ³Department of Oncology, Tianjin Central Hospital of Gynecology Obstetrics, Changjiang Road, Nankai District, Tianjin 300100, China. *Equal contributors.

Received January 5, 2015; Accepted February 15, 2015; Epub February 15, 2015; Published March 1, 2015

Abstract: *Background:* The function of iASPP (inhibitory member of the ASPP family) in cervical adenocarcinoma remains unknown. The aim of this study was to explore the expression and clinical relevance of iASPP in early stage cervical adenocarcinoma. *Methods* The clinical data of 75 patients with FIGO stage IA2-IIA cervical adenocarcinoma who were treated with radical hysterectomy from January 2004 to March 2008 was collected. The mRNA and protein expression levels of iASPP from the paired tumor specimens and adjacent normal cervical tissues were determined by real-time qRT-PCR and Western blot, and its relationship with clinicopathologic factors and prognosis of cervical cancer patients was retrospectively analyzed. *Results:* The mRNA and protein expression levels of iASPP were significantly elevated in cervical cancer tissues. The increased iASPP expression was correlated strongly with higher FIGO staging ($p = 0.034$), worse differentiation ($p = 0.046$), less pelvic lymph node metastasis ($p = 0.014$), and poor overall and disease-free survival of patients with cervical cancer (both $P < 0.05$). Multivariate Cox analysis indicated that high iASPP expression was an independent prognostic factor ($P < 0.05$). *Conclusions:* This study demonstrates that iASPP is highly elevated in cervical adenocarcinoma, and that overexpression is an independent poor prognostic indicator for early stage cervical cancer patients, suggesting that iASPP might serve as a novel potential prognostic marker and therapeutic target for cervical adenocarcinoma.

Keywords: Cervical adenocarcinoma, radical hysterectomy, prognostic factors, iASPP

Introduction

Although the incidence of cervical cancer has decreased due to the increased implementation of cytological screening, cervical cancer is still the third most common and the second most frequent cause of cancer death in women worldwide [1, 2]. Compared with the decreased incidence of squamous cell carcinoma, the incidence of adenocarcinoma have increased significantly, which accounts for approximately 20% of all cervical cancers [3]. However, in early stage cervical cancer patients treated with radical surgery, several investigators have reported that patients with adenocarcinoma have a poorer prognosis than squamous cell carcinoma patients [4-11]. So, it is urgent to elucidate the precisely predictive factors and

carry out a personalized therapy in order to predict and improve the prognosis for these early stage cervical adenocarcinoma patients.

The apoptosis stimulating proteins of p53 (ASPP) family includes three members, ASPP1, ASPP2 and iASPP, which are identified as p53-interacting proteins. ASPP1 and ASPP2 enhance, whereas iASPP inhibits, the apoptotic functions of p53 [12]. iASPP is an evolutionarily conserved inhibitor of p53, and its overexpression has been reported in a variety of tumors [13-17]. Moreover, recent reports showed that the polymorphism of iASPP gene was associated with the susceptibility of breast cancer, lung cancer and other tumors [18, 19]. In addition, suppression of iASPP blocked cancer cells proliferation and enhanced their chemosensitivity

[20-25]. Recently, one study found that the elevated expression of iASPP correlates with poor prognosis in the squamous cell cervical cancer [26]. However, the relationship between iASPP expression and clinicopathological characteristics or prognosis of human cervical adenocarcinoma has not been shown.

In the light of these considerations, the aim of our study was to identify the clinical significance of iASPP expression in FIGO IA2-IIA stage cervical AC patients following radical hysterectomy in a single institute.

Patients and methods

Our study protocol was approved by the Institutional Review Board of our hospital.

Study population

Patients with cervical cancer admitted to the oncology between January 2004 to March 2008 were drawn from the hospital tumor registry. The inclusion criteria for this study included: (1) pathologically confirmed patients with FIGO IA2-IIA cervical adenocarcinoma; (2) patients who underwent radical hysterectomy and bilateral pelvic LN dissection; (3) patients who had matched fresh surgical specimens and adjacent normal cervical tissues; (4) the clinical data and the follow-up information were complete. The exclusion criteria included: (1) patients who underwent palliative surgery; (2) patients who had distant metastasis or peritoneal dissemination that was confirmed during the operation; (3) patients who died during the initial hospital stay or within 1 month after surgery; and (4) patients who were lost to follow-up. Based on these inclusion and exclusion criteria, a total of 75 cervical adenocarcinoma patients presented with FIGO IA2-IIA stage following a curative resection. Among these patients, 33 (44.0%) cases received 2-3 cycles of chemotherapy before operation. The chemotherapy regimens were paclitaxel at 175 mg/m² on day 1, cisplatin at 60 mg/m² on day 1; repeated every 3 weeks. 44 (58.7%) patients had deep cervical stromal invasion and received radiation treatment after the operation. A total of 50.0 Gy was prescribed and delivered at 2.0 Gy per fraction, once daily, with five fractions per week.

Data collection

The patient characteristics and surgical and pathological findings were collected from the

institution's cervical cancer database, as well as from each patient's medical chart. And the long-term outcome was evaluated by comparing survival rate. Total follow-up time was defined as time in months from date of operation to last clinic visit or correspondence with the institutional tumor registry. Enhancement CT was performed for diagnosis of recurrence or progression when the results of B ultrasonography, CT scan, or chest X-ray were positive.

RNA preparation, quantitative real-time PCR

Total RNA was isolated from the 75 matched fresh surgical specimens and adjacent normal cervical tissues using Trizol reagent (Invitrogen) according to the manufacturer's instruction. Real-time qRT-PCR was performed according to the manufacturer's instructions (Applied Biosystem). The primers were as follows:

iASPP: forward 5'-TCTCCTCTGGCCAGCGACCG-3', reverse 5'-CTGCGAGGCAAAGTGCCCGA-3'; D-glyceraldehyde-3-phosphate dehydrogenase (GAPDH): forward 5'-CCATCAATGACCCCTTCATG-3', reverse 5'-GACGGTGCCATGGAATTT-3'. The results of the real-time qRT-PCR were analyzed by using the 2^{-ΔΔCt} method. Relative mRNA expression of iASPP gene (R) was calculated following the formula: R = densitometric units of iASPP/densitometric units of GAPDH.

Western blot

Total of 75 paired fresh tumor tissues and adjacent normal tissues were homogenized in NP40 lysis buffer [50 mM Tris-HCl (pH 8.0), 150 mM NaCl, 1% NP₄₀, 100 mM NaF, 200 μM Na₃VO₄], and incubated for 60 min at 4°C while rocking. Lysates were cleared by centrifugation (10 min at 12,000 rpm, 4°C). For Western blot analysis, equal amounts of total protein were separated by SDS-PAGE. The proteins were transferred to polyvinylidene fluoride (PVDF) membranes, blocked and incubated with the appropriate primary antibodies and then probed with secondary antibody for 1.5 h at room temperature. Signals were detected using enhanced chemiluminescence substrate (Perkin-Elmer Life Sciences). Quantification of the Western blot data were performed by measuring the intensity of the hybridization signals using the Image analysis program (Fluor-Chem™ 8900, Alpha Inotech). Relative protein expression of iASPP gene (R) was calculated following the formula:

iASPP in cervical adenocarcinoma prognosis

Table 1. Clinical/pathological characteristics of 75 cervical adenocarcinoma patients by iASPP protein expression level

Variables	Number	iASPP expression level		χ^2	P value
		Low (n = 40)	High (n = 35)		
Age (years)				$\chi^2 = 1.078$	0.351
≤ 45	25 (33.3%)	12 (30.0%)	13 (37.1%)		
> 45	50 (66.7%)	28 (70.0%)	22 (62.9%)		
Tumor size				$\chi^2 = 1.077$	0.299
≤ 4 cm	34 (45.3%)	19 (47.5%)	15 (42.8%)		
> 4 cm	41 (54.7%)	21 (52.5%)	20 (57.2%)		
FIGO staging					0.034
IA2	5 (6.7%)	4 (10.0%)	1 (2.8%)		
IB1	41 (54.6%)	25 (62.5%)	16 (45.7%)	$\chi^2 = 4.519$	
IB2	9 (12.0%)	4 (10.0%)	5 (14.3%)		
IIA	20 (26.7%)	7 (17.5%)	13 (37.2%)		
Tumor grade					0.046
Grade I	7 (9.4%)	6 (15.0%)	1 (2.8%)		
Grade II	28 (37.3%)	16 (40.0%)	12 (34.3%)		
Grade III	40 (53.3%)	18 (45.0%)	22 (62.9%)	$\chi^2 = 4.436$	
Deep cervical stromal invasion					0.054
No	31 (42.3%)	18 (45.0%)	13 (37.1%)		
Yes	44 (58.7%)	22 (55.0%)	22 (62.9%)	$\chi^2 = 7.654$	
Pelvic lymph node metastasis					0.014
No	44 (58.7%)	28 (70.0%)	16 (45.7%)		
Yes	31 (42.3%)	12 (30.0%)	19 (54.3%)	$\chi^2 = 6.646$	
Neoadjuvant chemotherapy					0.898
No	42 (56.0%)	24 (60.0%)	18 (51.4%)		
Yes	33 (44.0%)	16 (40.0%)	17 (48.6%)	$\chi^2 = 7.694$	

R = densitometric units of iASPP/densitometric units of GAPDH. And we found that the median iASPP relative protein expression level in tumor specimens was 1.31, we defined high iASPP expression as over 1.31 (> 1.31). Accordingly, the iASPP protein expression levels were further divided into high and low levels using median expression level as the cut-off point for analysis.

Statistical analysis

All statistical analyses were performed by using SPSS version 21.0 (SPSS, Chicago, IL, United States). The iASPP protein expression levels were further divided into high and low levels using median expression level as the cut-off point for analysis. Paired t test was used to compare the difference of iASPP level between cancer and normal specimens. χ^2 test was performed to explore the correlation between the expression of iASPP and clinicopathologic

parameters. The Kaplan-Meier method and log-rank tests were employed to correlate the gene expression levels and patient survival in univariate analysis. Multivariate Cox-regression analyses were conducted to identify independent prognostic factors [27]. *p*-Values (two sides) < 0.05 were considered statistically significant.

Results

Clinicopathological characteristics

Table 1 summarizes the complete clinicopathological characteristics of the 75 cervical patients with a diagnosis of adenocarcinoma. Of these, 33 patients (44.0%) received neoadjuvant chemotherapy. 5 patients (6.7%) had stage IA2 disease, 41 patient (54.6%) had stage IB1 disease, 9 patients (12.0%) had stage IB2 disease, 20 patients (26.7%) had stage IIA disease. The median age of the

iASPP in cervical adenocarcinoma prognosis

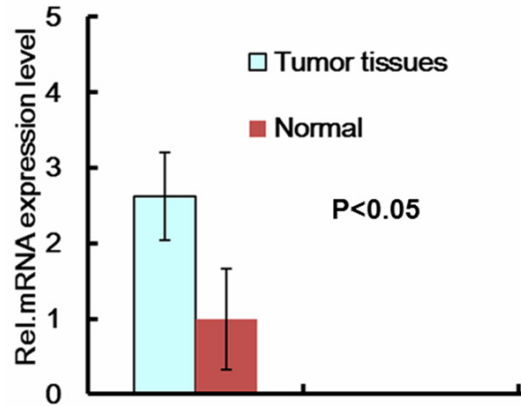


Figure 1. mRNA expression level of iASPP. Real-time qRT-PCR of iASPP mRNA expression in cervical adenocarcinoma tissues and adjacent normal cervical tissues. The results of the real-time qRT-PCR were analyzed using the $2^{-\Delta\Delta Ct}$ method.

patients was 56 years (range 23-85 years), while the median follow-up for all patients were 68.5 months (range, 0.5-108 months).

Significant differences were observed in FIGO staging ($p = 0.034$), tumor grade ($p = 0.046$), pelvic lymph node metastasis ($p = 0.014$). However, the two groups did not differ with respect to age, tumor size, deep cervical stromal invasion, and with/without new adjuvant chemotherapy.

iASPP expression was elevated in cervical adenocarcinoma

The iASPP mRNA expression in adenocarcinoma tissues was higher than that of control, the median elevated fold was 2.62 (**Figure 1**). Consistently, as the **Figure 2A** showed, the protein expression of iASPP in cancer tissues was also significantly higher than that of nontumorous cervical tissues. And the relative levels of iASPP protein were calculated, the median elevated fold was 2.45 (**Figure 2B**).

Survival outcomes

Figure 3 shows cumulative survival curves for the cervical adenocarcinoma patients. As the **Figure 3A** showed, the 5-year overall survival (OS) was statistically worse in the high iASPP expression group compared to low iASPP expression group (rate: 54.3% vs 95.0%, $p = 0.019$), and also the patients with high iASPP expression had shorter 5-year disease-free sur-

vival (DFS) than patients with low iASPP expression (40.0 vs. 85.0 %, $p < 0.001$, **Figure 3B**).

Multivariate analysis was performed using logistic regression on age ($p = 0.041$), FIGO staging ($p = 0.001$), tumor grade ($p = 0.025$), pelvic lymph node metastasis ($p = 0.006$), iASPP expression ($p = 0.008$), which were all significant on the univariate analysis (**Table 2**). It was observed that for the cervical adenocarcinoma patients, the statically significant independent prognosis factors were iASPP expression [hazard ratio (HR), 1.256; 95% CI, 1.036-1.465; $p = 0.023$], FIGO staging [hazard ratio (HR), 1.465; 95% CI, 1.135-1.637; $p = 0.039$], tumor grade [hazard ratio (HR), 1.243; 95% CI, 1.066-1.445; $p = 0.019$] and pelvic lymph node metastasis [hazard ratio (HR), 1.403; 95% CI, 1.179-1.613; $p = 0.003$] (**Table 2**).

Discussion

Despite the increased implementation of cytological screening and decreased incidence of cervical squamous cell carcinoma, the incidence of adenocarcinoma has increased significantly [2, 3]. What's worse, the patients with early stage adenocarcinoma have a poorer prognosis, and the improvement the prognosis of these early stage cervical AC patients remains clinically challenging [4-6, 11, 28]. As a new member of the ASPP family of proteins, iASPP has been found to be overexpressed and play an important role in suppressing apoptosis, regulating cancer cell proliferation in many human cancers [13-15, 29]. Unfortunately, the expression profile and the role of iASPP in cervical adenocarcinoma patients, especially the early stage patients remain unclear.

In our present study, we first identified the iASPP expression data in early stage cervical adenocarcinoma, identified the association of its expression with clinicopathologic factors and the long-term prognosis. Our results showed that both mRNA and protein levels of iASPP were over-expressed in cervical AC tissues. Furthermore, our study also identified that the elevated iASPP expression was correlated with higher FIGO staging ($p = 0.034$), worse differentiation ($p = 0.046$), more pelvic lymph node metastasis ($p = 0.014$), and poor overall and disease-free survival of patients with cervical cancer (both $P < 0.05$). Moreover,

iASPP in cervical adenocarcinoma prognosis

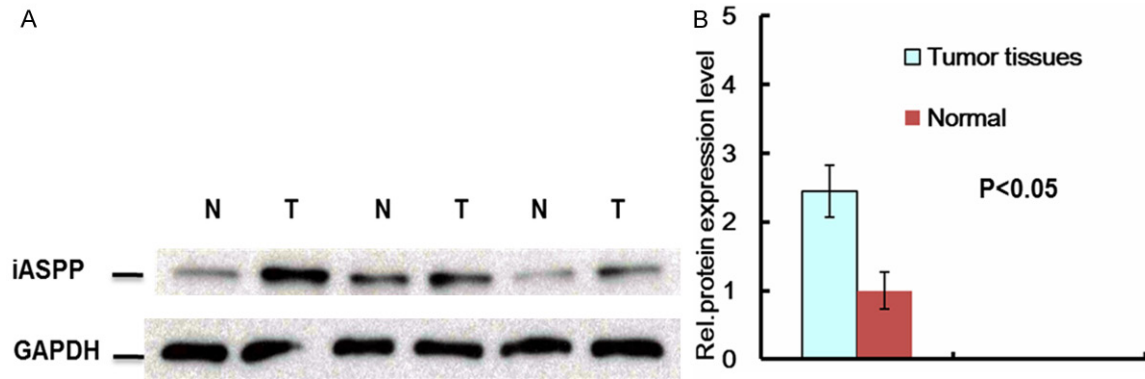


Figure 2. Protein expression levels of iASPP in in cervical adenocarcinoma tissues and adjacent normal cervical tissues. A. iASPP protein expression levels were detected by Western blot. B. The relative levels of iASPP protein expression.

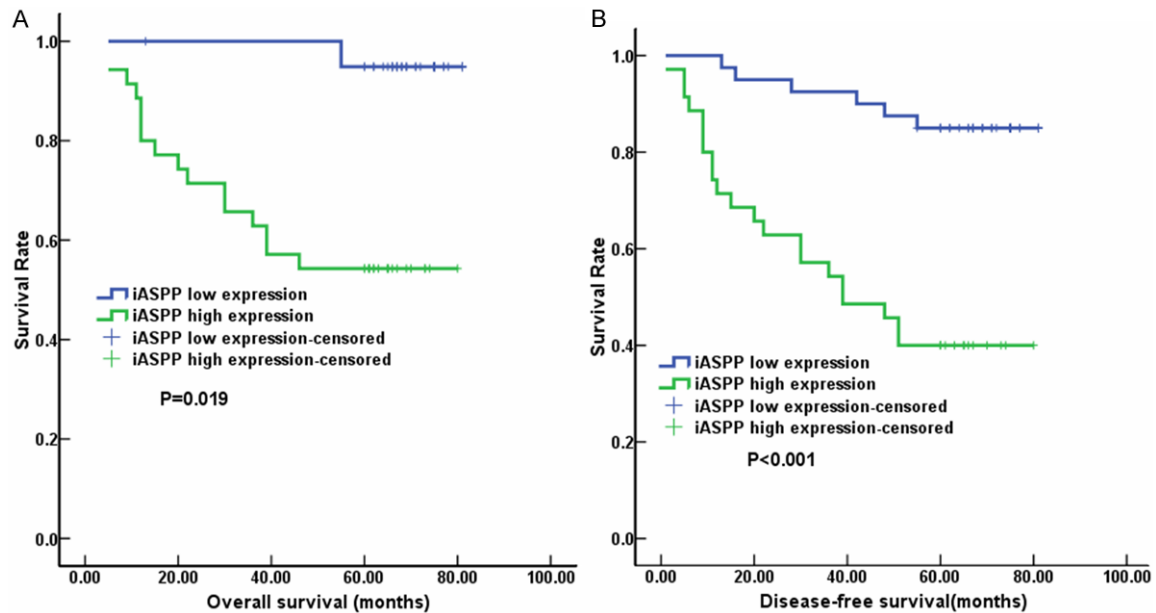


Figure 3. Overall and disease-free survival curves of early stage cervical adenocarcinoma patients with iASPP protein expression. A. The 5-year overall survival was significantly shorter in the high iASPP expression group compared to low iASPP expression group (OS: 54.3% vs 95.0%, $p = 0.019$). B. The patients with high iASPP expression had shorter 5-year disease-free survival (DFS) than patients with low iASPP expression (40.0 vs. 85.0 %, $p < 0.001$).

we confirmed that iASPP expression was an independent prognostic factor for long-term outcome. These data indicated the iASPP, as a newly identified oncoprotein, was involved in the carcinogenesis and progression of early stage cervical adenocarcinoma, and might serve as novel potential therapeutic target.

iASPP has been found to be overexpressed and play an important role in many kinds of human cancers, and the pro-tumor mechanisms are complicated. As a newly identified oncoprotein,

iASPP can promote cell proliferation and the tumor growth, inhibit apoptosis [16, 20-22, 30]. Additionally, the crucial role of iASPP in keratinocytes biology and controlling epithelial stratification has been revealed [31, 32]. Recently, the potential prognostic value of iASPP has been identified in ovarian cancer, hepatocellular carcinoma, head and neck squamous cell carcinoma, and the early stage squamous cell cervical cancer [15, 26, 33, 34]. In the present study, our data showed that the 5-year OS and DFS was significantly shorter in the high iASPP

iASPP in cervical adenocarcinoma prognosis

Table 2. Univariate and multivariate analysis of factors influencing OS (n = 75)

Variable	Univariate analysis	Multivariate Cox regression	
	p-Value	HR (95% CI)	p-Value
Age (years)			
≤ 45			
> 45	0.041	1.129 (1.033-1.650)	0.471
Tumor size			
≤ 4 cm			
> 4 cm	0.640		—
FIGO staging			
IA2			
IB1			
IB2			
IIA	0.001	1.465 (1.135-1.637)	0.039
Deep cervical stromal invasion			
No	0.075		—
Yes			
Tumor grade			
Grade I			
Grade II	0.025	1.243 (1.066-1.445)	0.019
Grade III			
Pelvic lymph node metastasis	0.006	1.403 (1.179-1.613)	0.003
No			
Yes			
Neoadjuvant chemotherapy	0.487		—
Yes			
No			
iASPP expression	0.008	1.256 (1.036-1.465)	0.023
Low			
High			

HR: hazard ratio, CI: confidence interval.

expression group compared to low iASPP expression group (OS: 54.3% vs 95.0%, $p = 0.019$; DFS: 40.0 vs 85.0%, $p < 0.001$) in early stage cervical adenocarcinoma patients (**Figure 3**). Further multivariate Cox analysis confirmed that high iASPP expression was an independent poor prognostic factor for long-term outcome in patients with early stage cervical adenocarcinoma (**Table 2**). In addition, FIGO staging [hazard ratio (HR), 1.465; 95% CI, 1.135-1.637; $p = 0.039$], tumor grade [hazard ratio (HR), 1.243; 95% CI, 1.066-1.445; $p = 0.019$] and pelvic lymph node metastasis [hazard ratio (HR), 1.403; 95% CI, 1.179-1.613; $p = 0.003$] were also identified as independent prognostic factors for overall survival (**Table 2**), which was consistent with the results of Schmeler's study [35].

This study has notable strengths as well as potential limitations. The important strengths of our study include its large size, accuracy of mRNA and protein measurements performed from the fresh surgical specimens of cervical cancer, and rigorous collection of survival data during an extended follow-up period. Limitations include the measurement of total iASPP protein expression versus cytoplasmic iASPP expression and nuclear iASPP expression separately. Also, since some of the patients included in this study had neoadjuvant and adjuvant therapies, which might have effect on iASPP expression and outcome. Accordingly, further study needs to be conducted to fully understand the molecular mechanism involved in these results.

Conclusions

The findings of this study demonstrates that iASPP is highly elevated in cervical adenocarcinoma, and it is an independent prognostic indicator of poor survival in early stage cervical adenocarcinoma patients, suggesting that

iASPP might serve as a novel potential prognostic marker and therapeutic target for cervical adenocarcinoma.

Acknowledgements

This work is supported by the National Natural Science Foundation of China (No. 81273937 and No. 81403220). We thanks Jennifer Lee for critical reading of the manuscript.

Disclosure of conflict of interest

None.

Address correspondence to: Yingjie Jia or Fanming Kong, Department of Oncology, First Teaching Hospital of Tianjin University of TCM, Anshanxi Road,

Nankai District, Tianjin, China, 300193. Tel: 86-22-27432431; Fax: 86-22-27432431; E-mail: jia-yingjie1616@163.com (YJJ); kongfanning08@163.com (FMK)

References

- [1] Jemal A, Bray F, Center MM, Ferlay J, Ward E and Forman D. Global cancer statistics. *CA Cancer J Clin* 2011; 61: 69-90.
- [2] Wang SS, Sherman ME, Hildesheim A, Lacey JV Jr and Devesa S. Cervical adenocarcinoma and squamous cell carcinoma incidence trends among white women and black women in the United States for 1976-2000. *Cancer* 2004; 100: 1035-1044.
- [3] Kjorstad KE. Adenocarcinoma of the uterine cervix. *Gynecol Oncol* 1977; 5: 219-223.
- [4] Nakanishi T, Ishikawa H, Suzuki Y, Inoue T, Nakamura S and Kuzuya K. A comparison of prognoses of pathologic stage Ib adenocarcinoma and squamous cell carcinoma of the uterine cervix. *Gynecol Oncol* 2000; 79: 289-293.
- [5] Lee YY, Choi CH, Kim TJ, Lee JW, Kim BG, Lee JH and Bae DS. A comparison of pure adenocarcinoma and squamous cell carcinoma of the cervix after radical hysterectomy in stage IB-IIA. *Gynecol Oncol* 2011; 120: 439-443.
- [6] Park JY, Kim DY, Kim JH, Kim YM, Kim YT and Nam JH. Outcomes after radical hysterectomy in patients with early-stage adenocarcinoma of uterine cervix. *Br J Cancer* 2010; 102: 1692-1698.
- [7] Hopkins MP and Morley GW. A comparison of adenocarcinoma and squamous cell carcinoma of the cervix. *Obstet Gynecol* 1991; 77: 912-917.
- [8] Berek JS, Hacker NF, Fu YS, Sokale JR, Leuchter RC and Lagasse LD. Adenocarcinoma of the uterine cervix: histologic variables associated with lymph node metastasis and survival. *Obstet Gynecol* 1985; 65: 46-52.
- [9] Kleine W, Rau K, Schwoeerer D and Pfeleiderer A. Prognosis of the adenocarcinoma of the cervix uteri: a comparative study. *Gynecol Oncol* 1989; 35: 145-149.
- [10] Chen RJ, Lin YH, Chen CA, Huang SC, Chow SN and Hsieh CY. Influence of histologic type and age on survival rates for invasive cervical carcinoma in Taiwan. *Gynecol Oncol* 1999; 73: 184-190.
- [11] Irie T, Kigawa J, Minagawa Y, Itamochi H, Sato S, Akeshima R and Terakawa N. Prognosis and clinicopathological characteristics of Ib-IIb adenocarcinoma of the uterine cervix in patients who have had radical hysterectomy. *Eur J Surg Oncol* 2000; 26: 464-467.
- [12] Sullivan A and Lu X. ASPP: a new family of oncogenes and tumour suppressor genes. *Br J Cancer* 2007; 96: 196-200.
- [13] Bergamaschi D, Samuels Y, O'Neil NJ, Trigiante G, Crook T, Hsieh JK, O'Connor DJ, Zhong S, Campargue I, Tomlinson ML, Kuwabara PE and Lu X. iASPP oncoprotein is a key inhibitor of p53 conserved from worm to human. *Nat Genet* 2003; 33: 162-167.
- [14] Zhang X, Wang M, Zhou C, Chen S and Wang J. The expression of iASPP in acute leukemias. *Leuk Res* 2005; 29: 179-183.
- [15] Lu B, Guo H, Zhao J, Wang C, Wu G, Pang M, Tong X, Bu F, Liang A, Hou S, Fan X, Dai J, Wang H and Guo Y. Increased expression of iASPP, regulated by hepatitis B virus X protein-mediated NF-kappaB activation, in hepatocellular carcinoma. *Gastroenterology* 2010; 139: 2183-2194 e2185.
- [16] Chen J, Xie F, Zhang L and Jiang WG. iASPP is over-expressed in human non-small cell lung cancer and regulates the proliferation of lung cancer cells through a p53 associated pathway. *BMC Cancer* 2010; 10: 694.
- [17] Liu WK, Jiang XY, Ren JK and Zhang ZX. Expression pattern of the ASPP family members in endometrial endometrioid adenocarcinoma. *Onkologie* 2010; 33: 500-503.
- [18] Deng Q, Sheng L, Su D, Zhang L, Liu P, Lu K and Ma S. Genetic polymorphisms in ATM, ERCC1, APE1 and iASPP genes and lung cancer risk in a population of southeast China. *Med Oncol* 2010;
- [19] Nexø BA, Vogel U, Olsen A, Nyegaard M, Bukowy Z, Rockenbauer E, Zhang X, Koca C, Mains M, Hansen B, Hedemand A, Kjeldgaard A, Laska MJ, Raaschou-Nielsen O, Cold S, Overvad K, Tjonneland A, Bolund L and Borglum AD. Linkage disequilibrium mapping of a breast cancer susceptibility locus near RAI/PPP1R13L/iASPP. *BMC Med Genet* 2008; 9: 56.
- [20] Li G, Wang R, Gao J, Deng K, Wei J and Wei Y. RNA interference-mediated silencing of iASPP induces cell proliferation inhibition and G0/G1 cell cycle arrest in U251 human glioblastoma cells. *Mol Cell Biochem* 2011; 350: 193-200.
- [21] Liu T, Li L, Yang W, Jia H, Xu M, Bi J, Li Z, Liu X, Jing H and Kong C. iASPP is important for bladder cancer cell proliferation. *Oncol Res* 2011; 19: 125-130.
- [22] Lin BL, Xie DY, Xie SB, Xie JQ, Zhang XH, Zhang YF and Gao ZL. Down-regulation of iASPP in human hepatocellular carcinoma cells inhibits cell proliferation and tumor growth. *Neoplasma* 2011; 58: 205-210.
- [23] Liu H, Wang M, Diao S, Rao Q, Zhang X, Xing H and Wang J. siRNA-mediated down-regulation of iASPP promotes apoptosis induced by etoposide and daunorubicin in leukemia cells expressing wild-type p53. *Leuk Res* 2009; 33: 1243-1248.

iASPP in cervical adenocarcinoma prognosis

- [24] Liu ZJ, Cai Y, Hou L, Gao X, Xin HM, Lu X, Zhong S, Gu SZ and Chen J. Effect of RNA interference of iASPP on the apoptosis in MCF-7 breast cancer cells. *Cancer Invest* 2008; 26: 878-882.
- [25] Llanos S, Royer C, Lu M, Bergamaschi D, Lee WH and Lu X. Inhibitory member of the apoptosis-stimulating proteins of the p53 family (iASPP) interacts with protein phosphatase 1 via a noncanonical binding motif. *J Biol Chem* 2011; 286: 43039-43044.
- [26] Cao L, Huang Q, He J, Lu J and Xiong Y. Elevated expression of iASPP correlates with poor prognosis and chemoresistance/radioresistance in FIGO 1b1-11a squamous cell cervical cancer. *Cell Tissue Res* 2013; 352: 361-369.
- [27] Cox DR. Regression models and life-tables. *Journal of the Royal Statistical Society. Series B (Methodological)* 1972; 187-220.
- [28] Mabuchi S, Okazawa M, Matsuo K, Kawano M, Suzuki O, Miyatake T, Enomoto T, Kamiura S, Ogawa K and Kimura T. Impact of histological subtype on survival of patients with surgically-treated stage IA2-11B cervical cancer: adenocarcinoma versus squamous cell carcinoma. *Gynecol Oncol* 2012; 127: 114-120.
- [29] Cai Y, Qiu S, Gao X, Gu SZ and Liu ZJ. iASPP inhibits p53-independent apoptosis by inhibiting transcriptional activity of p63/p73 on promoters of proapoptotic genes. *Apoptosis* 2012; 17: 777-783.
- [30] Li J, Kang LN and Qiao YL. Review of the cervical cancer disease burden in mainland China. *Asian Pac J Cancer Prev* 2011; 12: 1149-1153.
- [31] Chikh A, Matin RN, Senatore V, Hufbauer M, Lavery D, Raimondi C, Ostano P, Mello-Grand M, Ghimenti C, Bahta A, Khalaf S, Akgul B, Braun KM, Chiorino G, Philpott MP, Harwood CA and Bergamaschi D. iASPP/p63 autoregulatory feedback loop is required for the homeostasis of stratified epithelia. *EMBO J* 2011; 30: 4261-4273.
- [32] Notari M, Hu Y, Koch S, Lu M, Ratnayaka I, Zhong S, Baer C, Pagotto A, Goldin R, Salter V, Candi E, Melino G and Lu X. Inhibitor of apoptosis-stimulating protein of p53 (iASPP) prevents senescence and is required for epithelial stratification. *Proc Natl Acad Sci U S A* 2011; 108: 16645-16650.
- [33] Jiang L, Siu MK, Wong OG, Tam KF, Lu X, Lam EW, Ngan HY, Le XF, Wong ES, Monteiro LJ, Chan HY and Cheung AN. iASPP and chemoresistance in ovarian cancers: effects on paclitaxel-mediated mitotic catastrophe. *Clin Cancer Res* 2011; 17: 6924-6933.
- [34] Liu Z, Zhang X, Huang D, Liu Y, Liu L, Li G, Dai Y, Tan H, Xiao J and Tian Y. Elevated expression of iASPP in head and neck squamous cell carcinoma and its clinical significance. *Med Oncol* 2012; 29: 3381-3388.
- [35] Schmeler KM, Frumovitz M and Ramirez PT. Conservative management of early stage cervical cancer: is there a role for less radical surgery? *Gynecol Oncol* 2011; 120: 321-325.